

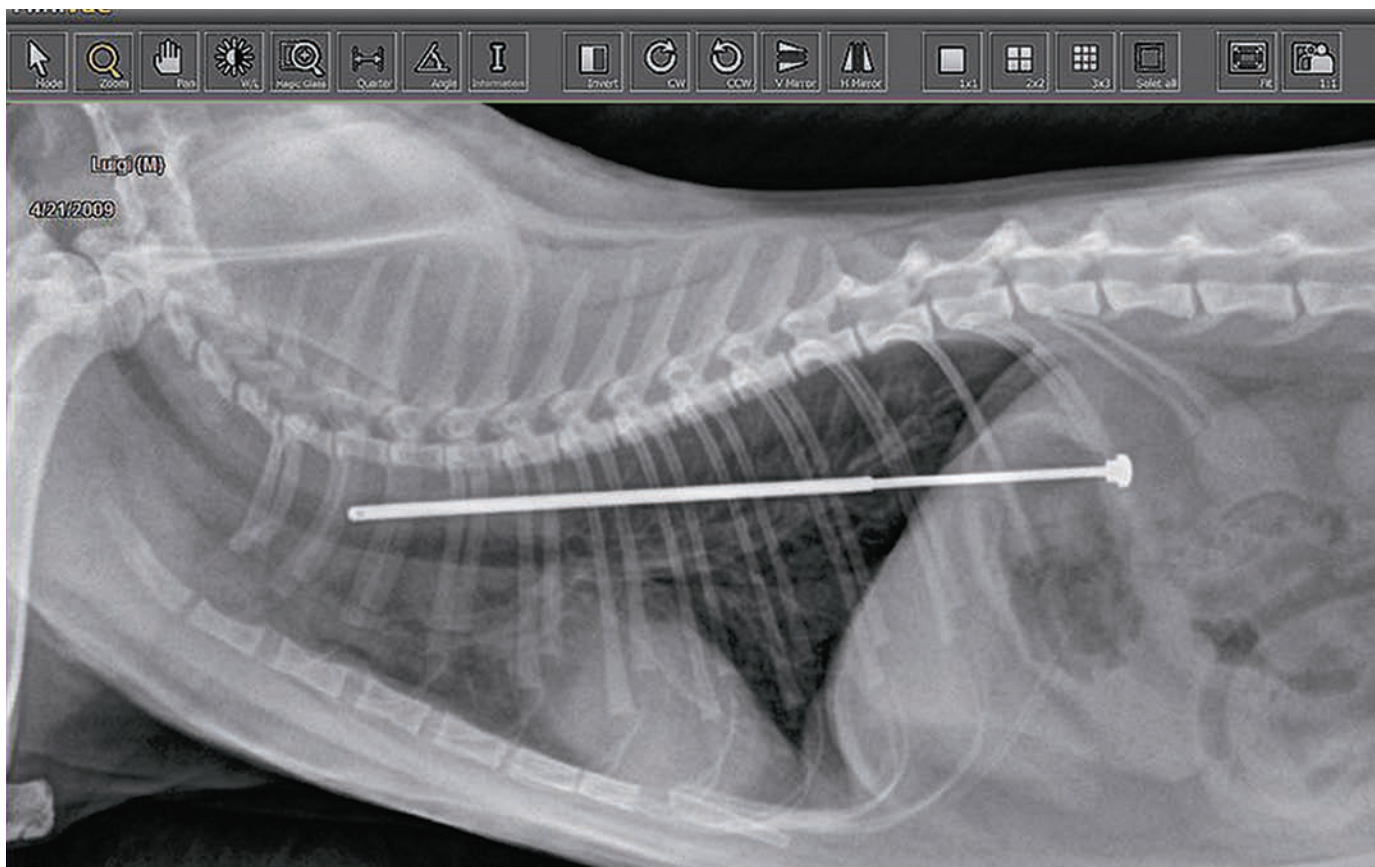
THEY ate **What?**

2009 Radiograph Contest

THE BEST OF OUR FOURTH ANNUAL COMPETITION

Veterinary Practice News thanks all readers who sent radiographs. 2009 winner Lawrence Gallagher, VMD, will receive a digital single-

lens reflex camera courtesy of contest sponsor Sound-Eklin of Carlsbad, Calif. The top two runners-up get point-and-shoot cameras.



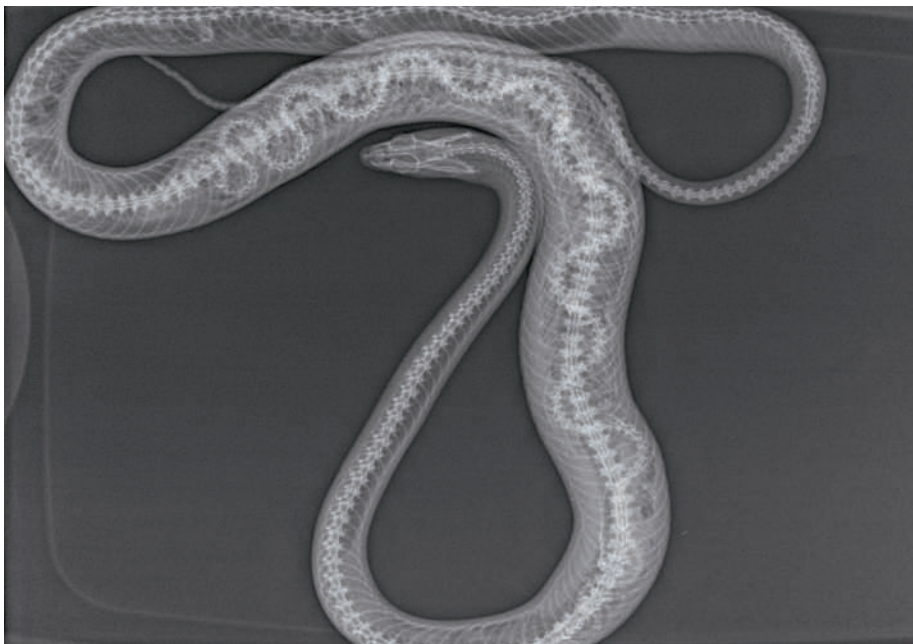
GRAND PRIZE WINNER

INTERFERENCE

Submitted by

Lawrence Gallagher, VMD
Bryn Mawr Veterinary Hospital
Bryn Mawr, Pa.

Luigi, a neutered 2-year-old Norwegian forest cat, was brought in one afternoon after vomiting for 36 hours. The owner, a physician, reported that Luigi was eating but would vomit afterward and at other times. The owner said the cat acted as if something was stuck in his throat. The owner became especially concerned when the last vomiting episode, 30 minutes before presentation, contained blood. On physical exam, Luigi appeared healthy. Radiographs showed a 5-inch-long antenna. Gastrotomy was performed that evening to remove the foreign object. Luigi fully recovered.



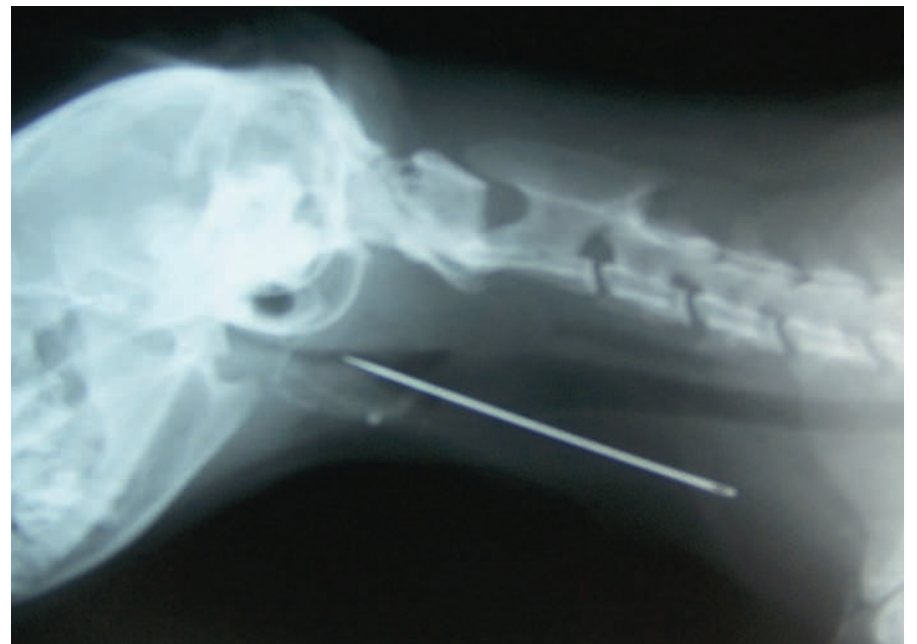RUNNER-UP

HIDE AND SEEK

Submitted by

Susan Logan, BS, CVT
Phoenix Zoo
Phoenix, Ariz.

Digital radiographs showed that a plump non-venomous Coachwhip had gotten the better of its roommate, a venomous sidewinder rattlesnake. The Coachwhip's greater length, girth and grumpy disposition gave it the advantage.



RUNNER-UP

TO THE POINT

Submitted by

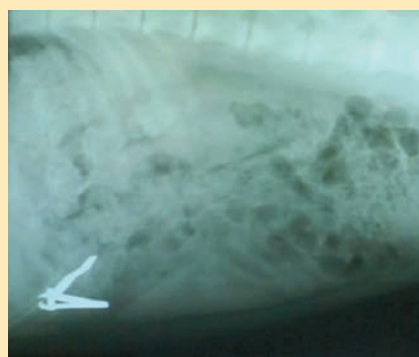
Bonnie Worthen, DVM, and Annette Pecak, LVT
Cat Hospital of Kitchener-Waterloo
Kitchener, Ontario, Canada

This cat was brought in because of an open abscess in its throat. An examination revealed a thread inside the hole. Radiographs showed a needle attached to the thread. A specialist removed the needle.

THEY ate **What?**

2009 Radiograph Contest

HONORABLE MENTION

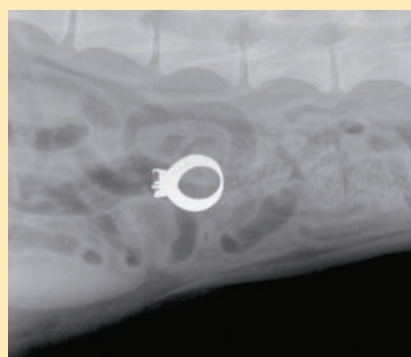


UNUSUAL FEAT

Submitted by

Sugar Creek Animal Hospital
Bentonville, Ark.

This 15-month-old black lab mix ate its owner's toenail clippers. After reviewing the radiographs, the veterinarian decided to induce vomiting rather than attempt surgery. The clippers came up shortly afterward.

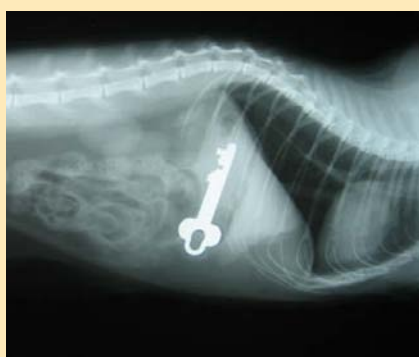

EXPENSIVE TASTES

Submitted by

Dr. Stan Kunin, DVM
Veterinary Medical Center
Woodland Hills, Calif.

The owner suspected that her male Standard Poodle had swallowed a \$10,000 diamond ring. It had. The ring passed naturally through the patient in three days.

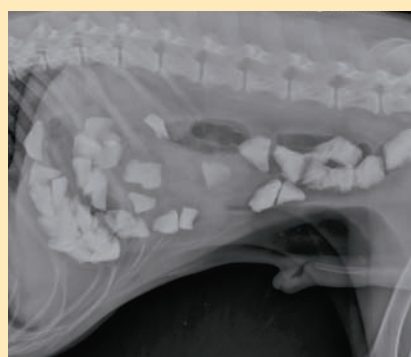

UNLOCKED MYSTERY

Submitted by

Dr. I. Mul, DVM
Lakeshore Animal Clinic
Kelowna, British Columbia, Canada

Willow, a year-old cat, ate a mailbox key that had three ribbons attached. She vomited up the ribbons, but the key stayed behind. Stomach surgery was successful.

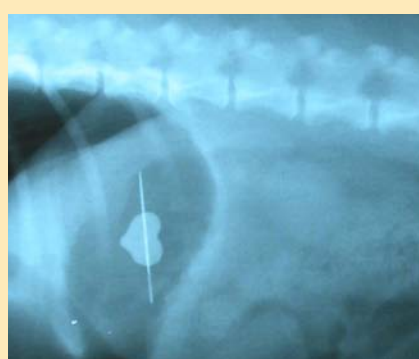


MORE ROUGHAGE

Submitted by

Michael G. Reed,
Veterinary Imaging Technician
VCA Animal Care Center of Sonoma County
Rohnert Park, Calif.

This border collie was lethargic and constipated. Radiographs indicated that the dog had ingested pieces of a driveway.

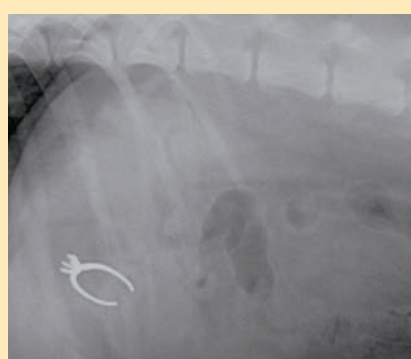


BE MY VALENTINE

Submitted by

Nancy C. Coleman, DVM
Greenville Animal Clinic and Hospital
Greenville, Miss.

This 6-month-old pug swallowed a cross-stitch needle. Radiographs revealed the needle in the stomach and a heart-shaped object the owner did not recognize. Gastrotomy took care of it.

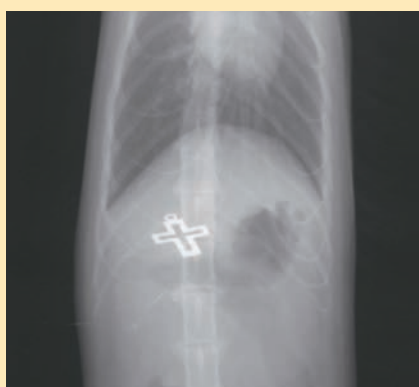

RING BEARER

Submitted by

Jonathan Bramson, DVM
Catoclin Veterinary Clinic
Thurmont, Md.

The owner of this food-aggressive dog had filled the dog's bowl. In one quick movement, the dog stripped the diamond engagement ring from her finger and swallowed it. It became lodged in the stomach.

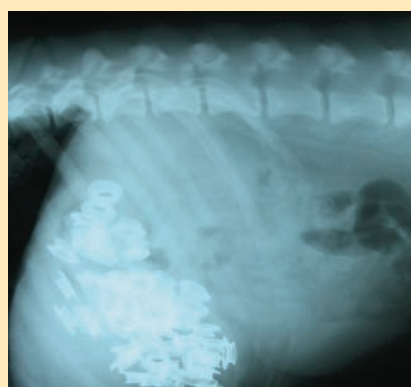


PRAY FOR HELP

Submitted by

Jennifer Adelini, DVM
Santa Clarita Animal Hospital
Santa Clarita, Calif.

A 3-year-old domestic shorthair cat was brought in because of vomiting and anorexia. Radiographs indicated an ingested metallic cross. Surgery was successful. Ironically, the owner's last name, Cruz, means "cross" in Spanish.



RIVETING

Submitted by

Andrea Razer, DVM
Hillcrest Animal Hospital
Little Rock, Ark.

A leather belt went missing after the owner of this pitbull mix unpacked from a trip. Radiographs revealed the remains of the belt, studded with many metal rivets, inside the dog. Exploratory laparotomy/gastrotomy was performed successfully.